

Although all airway skills are important, the most important skill, and perhaps the most difficult, is the ability to use a bag and mask to effectively oxygenate and ventilate a patient. While over the years there have been important advances in emergency airway management, such as alternative airways (e.g. Combitube), Bag-Valve Mask (BVM) ventilation is a life-saving skill that is often underappreciated. While BVM ventilation may seem mundane compared to placing an advanced airway (e.g. endotracheal tube, Combitube), it is actually a skill that is difficult to master. The false belief that BVM ventilation is an easy skill has led many health-care providers to mistakenly think they are proficient in this skill. **The purpose of this article is to review BVM ventilation and associated skills and techniques to effectively ventilate a patient. In the second half of this article is a review of some of the advanced airway tools and techniques.** While most applicable for Advanced Life Support (ALS) providers, it is beneficial for all personnel to have an awareness of them.

Proper positioning of the patient is a critical element for successful BVM ventilation. The classic teaching for both ventilation and intubation positioning is placing the patient in the “sniffing position” provided there are no spinal precautions that need to be taken. The purpose is to allow for proper alignment of the oropharyngeal axes (Figure 1).

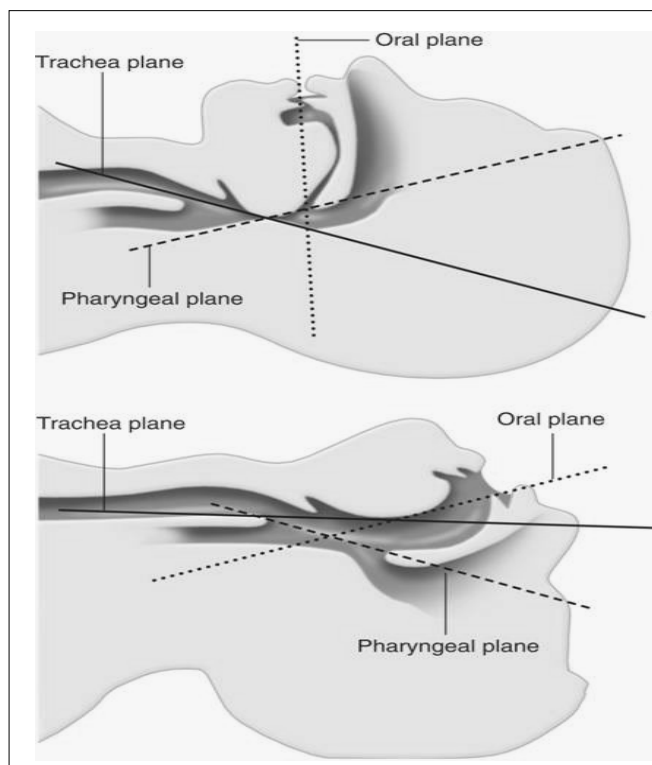
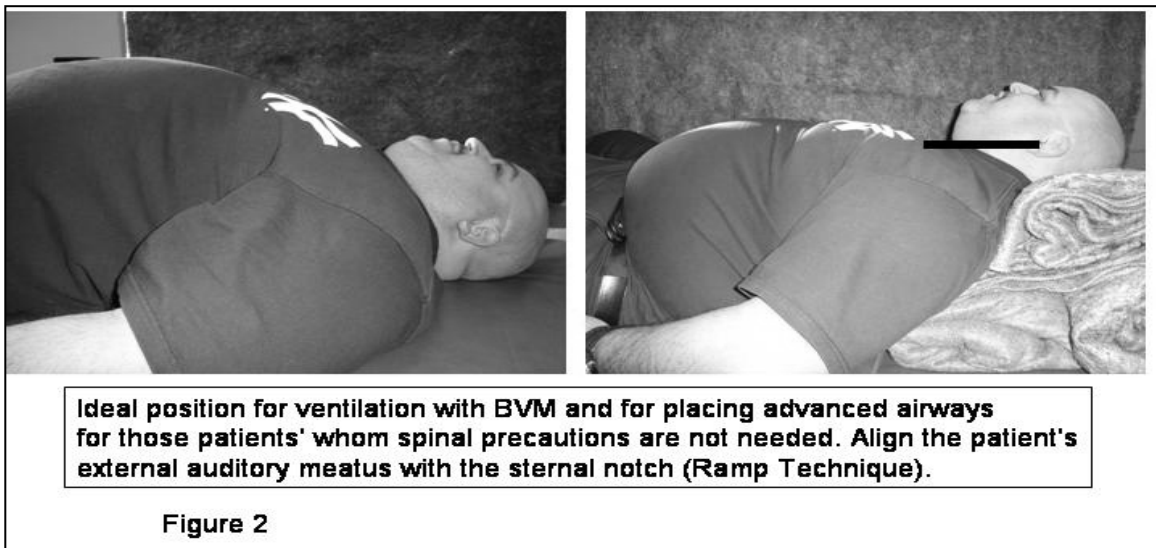
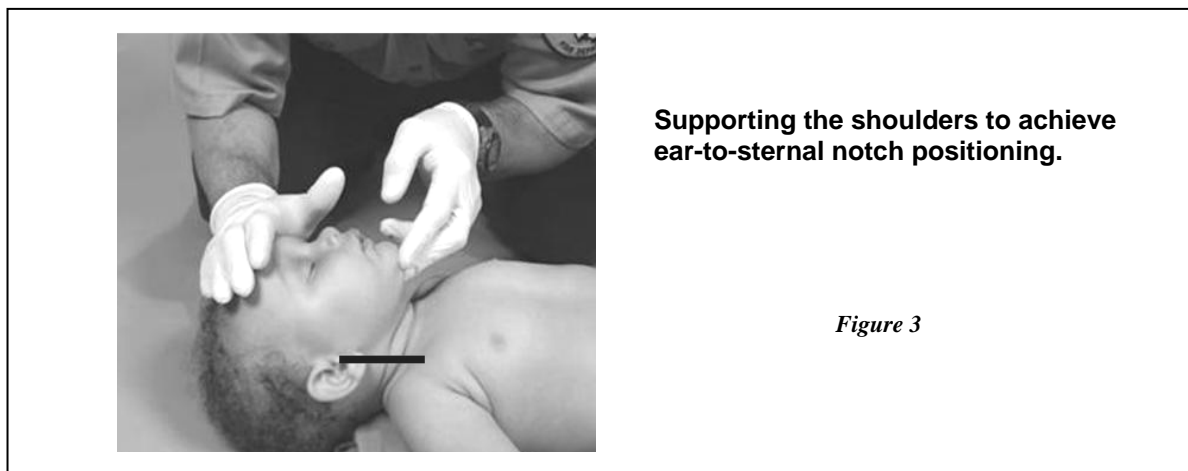

Figure 1

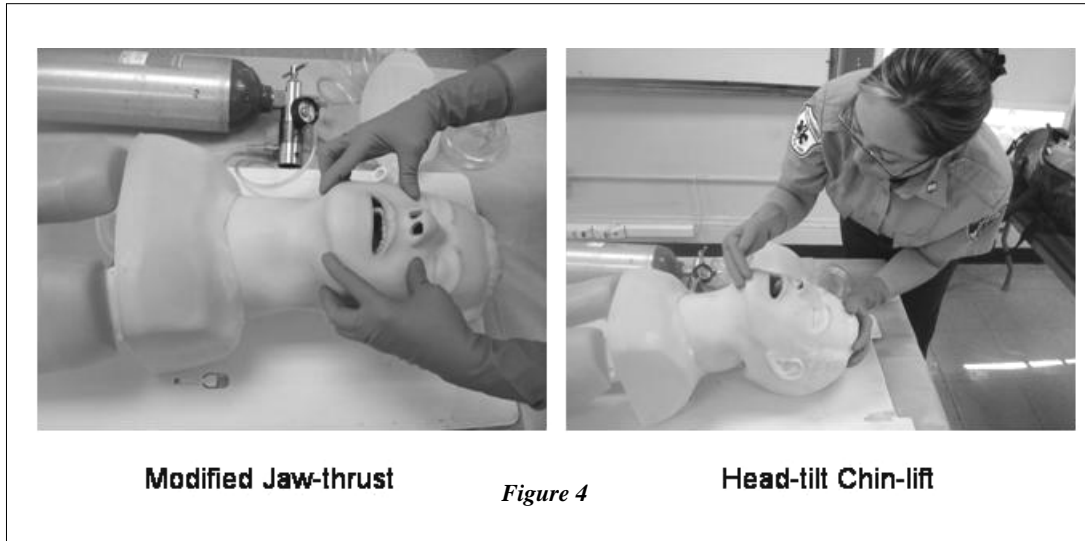
However, this still may be inadequate, especially for pediatric and obese patients. In these patients placing the patient in an ear-to-sternal notch position provides better alignment of the oropharyngeal axes than does the traditional “sniffing” position (Figure 2). This position causes the head to be flexed relative to



the chest, reproducing the position that patients in respiratory distress use, but in a supine position. The face should be approximately horizontal. This technique maximizes upper airway patency and improves the mechanics of ventilation independent of age or body habitus. In children, the proportionately large occiput causes the head to be flexed relative to the chest, without the need for additional head elevation. While in infants, the large occiput may cause excessive neck flexion requiring only support of the shoulders (Figure 3).

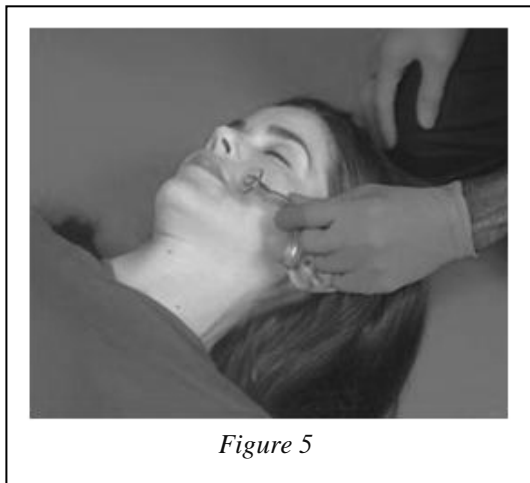

Additional maneuvers to assist in improving airway patency include the head tilt-chin lift and jaw thrust maneuvers (Figure 4). The head-tilt chin lift maneuver is used when no cervical spine injury is suspected. This requires the provider to use both hands with one hand applying downward pressure on the forehead while the other hand lifts the chin. The jaw thrust maneuver is safer for patients with suspected spinal injury. This is performed by placing both hands on the angles of the jaw (mandible) and both thumbs on the maxilla then displacing the mandible forward bringing the tongue with it to minimize its obstructing potential.



AIRWAY ADJUNCTS

One of the most underutilized pieces of equipment on the ambulance are airway adjuncts. These devices prevent the tongue from occluding the airway and provide an open airway for air to pass. There



are two types of adjuncts: oropharyngeal airway (OPA) and nasopharyngeal airway (NPA). They come in various sizes and it is imperative that the correct size is used. For the adult patient, the OPA is measured from the center of the mouth to the angle of the jaw or angle of the mouth to the tip of the earlobe (Figure 5). For pediatric patients it is measured from the corner of the mouth to the angle of the jaw.

When inserting the OPA, to avoid pushing the tongue posteriorly, grasp the mandible and tongue in one hand

and manually distract the jaw (tongue jaw lift), providing the patient will not bite. An alternative maneuver is to use a tongue blade and depress the tongue while inserting the airway. An OPA should only be used in patients who do not have an intact gag reflex which could induce vomiting, resulting in aspiration of vomitus into the lungs. Sometimes we may not appreciate that a gag reflex is present until an OPA placement is attempted. Immediately remove the OPA if a gag reflex is present.

The NPA is measured from the naris of the nose to the tip of the ear lobe (Figure 6). Lubricant jelly should be applied to the NPA tip to help assist in placement. In patients less than 1 year of age NPA's should not be used because the larger adenoidal tissue, when traumatized, can result in significant bleeding. The NPA should be used in patients who still have an intact gag reflex but are at risk of their tongue causing an airway obstruction (e.g. post-ictal patient or depressed mental status due to drug intoxication).

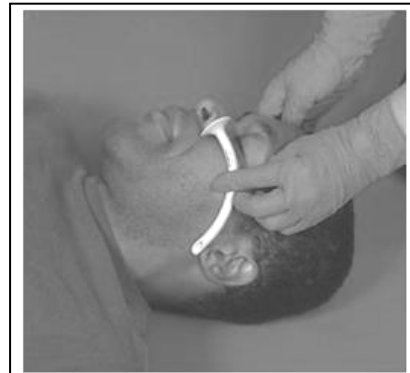

Figure 6

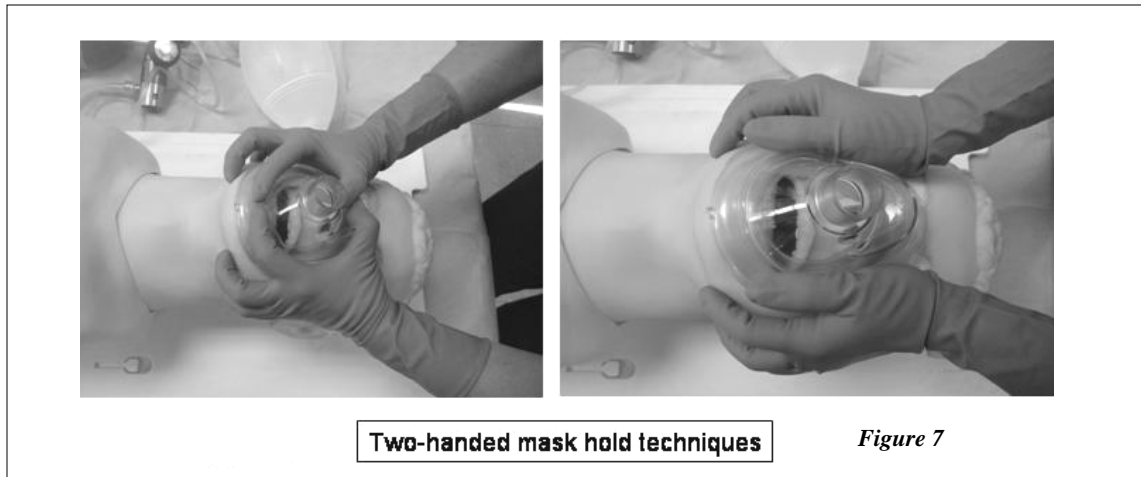
FACE-MASK SEAL

Correct mask sizing is important for both adult and pediatric patients in order to maintain a proper seal. This is measured from the bridge of the patient's nose to the cleft of the chin. A face mask that is too large, in addition to preventing a proper seal, may press on the patient's eyes causing a vagal bradycardia. Pressure on the eyes may also occur if you rest either of your wrists on the patient's orbits while ventilating. In addition to the vagal bradycardia, pressure on the eyes can significantly reduce retinal blood flow.

Obtaining an adequate seal between the face and the mask is one of the more challenging aspects of providing BVM ventilation. Traditionally, providers have used the one handed technique in the "EC" hand position. This position involves the thumb and index finger holding the mask and the three other fingers holding the mandible while providing a jaw thrust. The problem with this one handed technique is the common failure to provide an adequate seal due to an air leak, especially around the nasal bridge. That is why it is emphasized at the Bureau of Training that a two-handed mask technique should be used when there are adequate personnel present. There are two ways this may be accomplished: a bilateral "EC" hand position or place the sides of your thumbs along the long axis of the mask and then place the fingers under the mandible to apply a jaw lift (Figure 7, next page). This latter technique has been described as being a more comfortable position for the rescuer.

Mask ventilation may be difficult in edentulous (no teeth) patients due to the inability to perform a good seal. It is easier to ventilate with dentures in place and easier to intubate with them out. In patients

with beards you can use a water-soluble lubricant to flatten the facial hair or use an occlusive dressing over the face with a hole over the mouth opening.



VENTILATING THE PATIENT

Once proper position and seal are achieved then “bagging” the patient may begin. The adult and pediatric resuscitation bags, when fully inflated, contain 1500 and 650ml of oxygen, respectively. Normal tidal volumes (passive breathing) are about half of these volumes. Fully squeezing the bag will cause the stomach to become inflated with air. This will result in aspiration of the stomach contents into the lungs, significantly increasing the mortality rate for the patient. Other things that may increase the risk of inflating the stomach include high upper airway peak inspiratory pressures resulting from short inspiratory times and increased airway resistance due to incomplete airway opening. Several steps can be taken to minimize the risk of inflating the stomach. Each breath given to the patient should be given over 1-2 seconds with a tidal volume that is sufficient to only produce visible chest rise. The goal is to provide small tidal volumes while avoiding rapid or forceful breaths.

Hyperventilation can also have harmful effects for the patient. As was discussed during the past CORE at the Academy, hyperventilating the patient raises the intra-thoracic pressure which decreases the venous blood to the heart resulting in a decrease in cardiac output which reduces cerebral and coronary perfusion. Hyperventilation also causes cerebral vasoconstriction due to decreased CO₂ levels resulting in global cerebral ischemia. The rate of ventilation for an adult is 10-12 breaths per minute or approximately 1 bag squeeze every 5-6 seconds. The bag should be depressed for a full 1-2 seconds looking for visible chest rise. With the pediatric patient the rate of ventilation for infants is 20-30 breaths per minute and for older children, 16-20 breaths per minute.

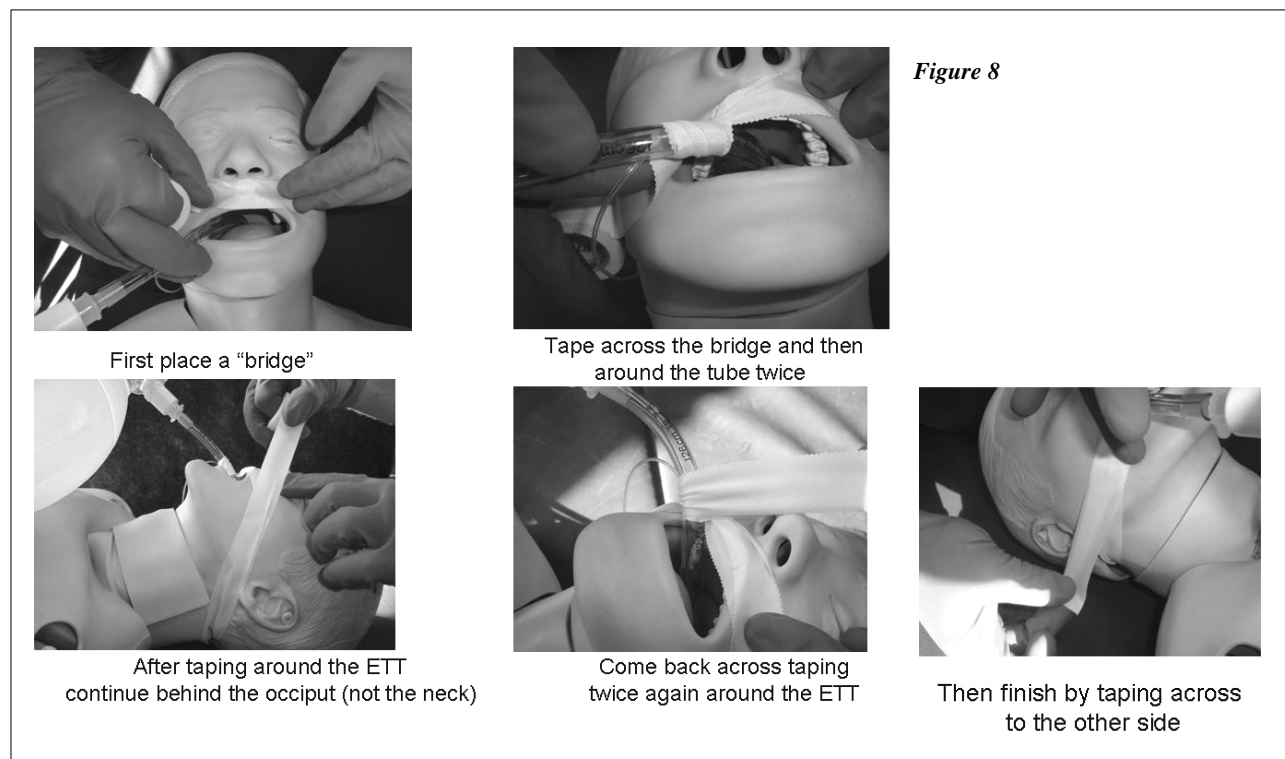
SELICK'S MANEUVER (CRICOID PRESSURE)

This maneuver was first described by Sellick in 1961. The technique is done by applying backward pressure on the cricoid cartilage (not thyroid cartilage) compressing the esophagus against the underlying C6 vertebrae. Theoretically by occluding the esophagus this would prevent the regurgitation and aspiration of stomach contents into the lungs. However, cricoid pressure has been shown to cause airway obstruction limiting the ability to ventilate the patient. Additionally, several recent studies have shown that cricoid pressure does not completely prevent aspiration. While this maneuver is still a common practice, you must be cognizant that if cricoid pressure is impeding ventilation that it should be lessened or release entirely. By taking the steps described above for proper ventilation (i.e. lower airway pressures, delivering breaths slowly and providing smaller tidal volumes) stomach inflation can be minimized.

ADVANCED AIRWAY ISSUES

Endotracheal Tube (ETT) Taping

Contrary to what many personnel think, commercial tube holders in studies have not shown an advantage over taping for securing the endotracheal tube. However this requires proper taping technique (Figure 8) and having the right tape. Below is a step-by-step approach for securing the endotracheal tube. It is important to tape along the maxilla and not the mandible, and along the lower occiput.



DISCONNECTING THE BVM

When moving an intubated patient, whether onto a stretcher or down a staircase, the BVM should be disconnected from the advanced airway. This will help prevent displacement of the airway device. On stairway landings, be sure to reconnect the BVM and give a few ventilations before continuing down the stairs.

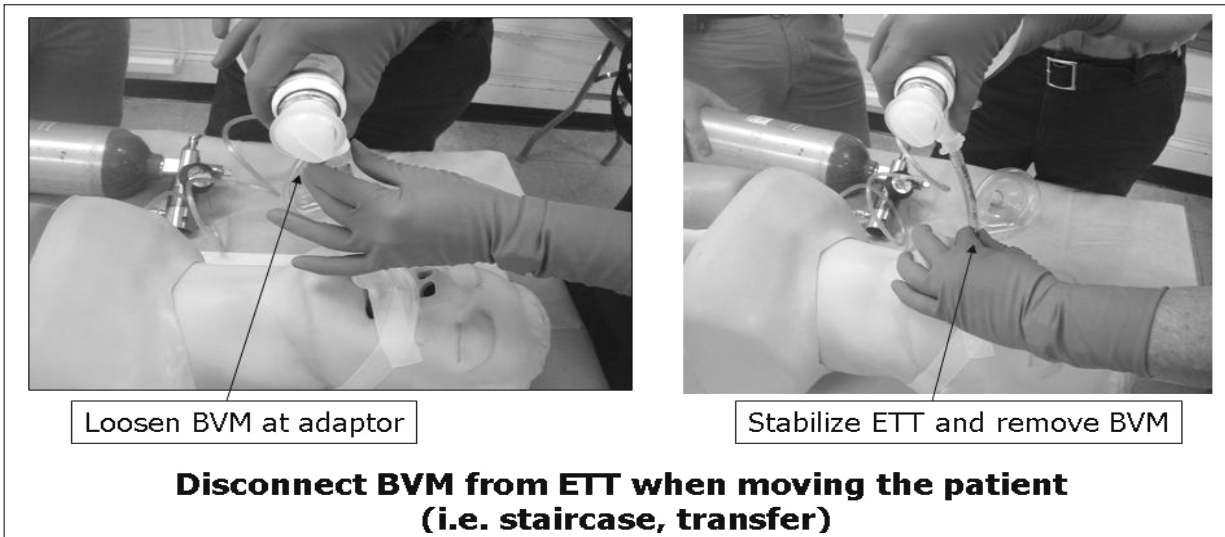


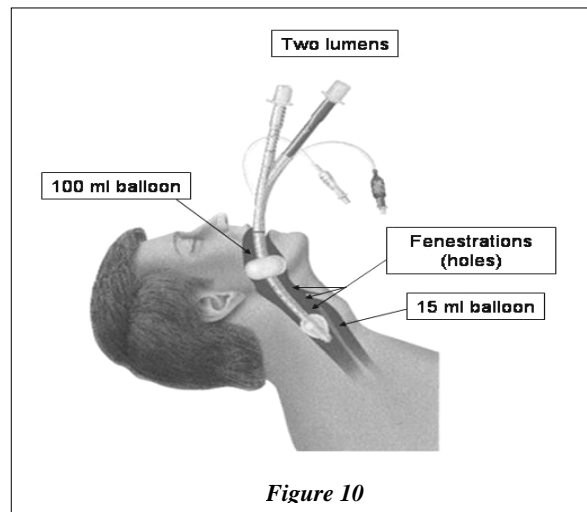
Figure 9

SUPRAGLOTTIC DEVICES

Over the last several years many supraglottic devices (alternative airways) have emerged in the prehospital setting. Our Department introduced Combitubes into the field last year with many subsequent success stories. These devices are used in patients who are not able to be ventilated with a BVM nor successfully intubated with an endotracheal tube. These devices serve as a bridge to successfully ventilate a patient until arrival at an emergency department where a definitive airway can be placed. Except for the Combitube, most of the other devices have only been around for a few years. While they are all FDA-approved for use, there are limited studies comparing the devices. Last year, the Regional Emergency Medical Advisory Committee (REMAC) approved the use of alternative airways. They did not dictate which device to use. This decision is left up to the agency's Medical Director. Below are the three most common being used. Personnel should be familiar with the devices as they may encounter them in the field. All of the devices work similar in that they are blindly inserted and occlude the esophagus while ventilating the trachea, but there are differences among them. There is no perfect device and each has advantages and disadvantages.

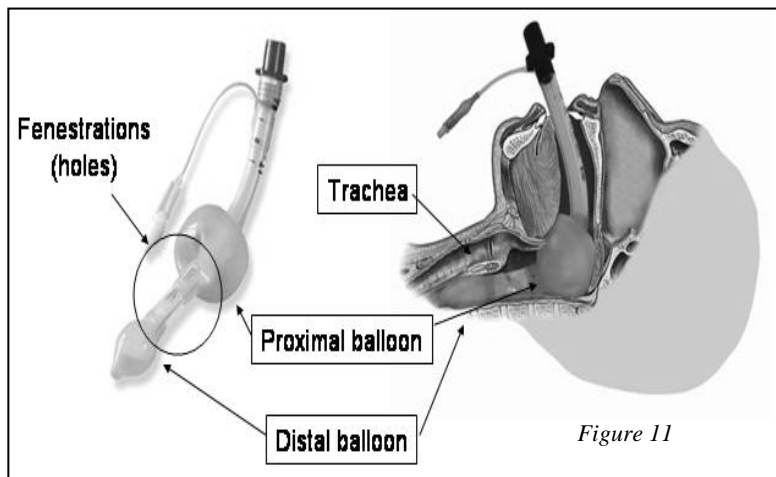
COMBITUBE

The Combitube (Figure 10) is a double-lumen device with balloon cuffs that are to be positioned below (in the esophagus) and above (hypopharyngeal) the glottis permitting ventilation through side fenestrations (holes). Combitube will enter the esophagus in ~ 95% of cases and in 5% of cases it will enter the trachea. It has the ability to ventilate the patient through either lumen. Some of the disadvantages associated with Combitube include injuries to the esophagus or airway (uncommon), difficulty inserting when the neck is immobilized, and that it is constructed with latex.



KING-LT

The King Airway (Figure 11) is a single lumen device. It has a small distal balloon at the tip and a larger balloon at the midportion of the tube. Both balloons are inflated simultaneously (unlike Combitube which requires the two balloons to be inflated separately) requiring only a single syringe. The distal balloon is positioned in the upper esophagus and the proximal balloon in the hypopharynx.



The advantages of the King Airway over the Combitube are that it is latex-free, easier to insert, and it has the ability to blindly change it over to an endotracheal tube by inserting a Bougie device (intubating stylet) through one of its fenestrations. It is designed to be inserted into the esophagus 100% of the time, however there is the chance that the device can be inadvertently placed into the trachea resulting in an inability to ventilate the patient.

LARYNGEAL MASK AIRWAY (LMA)

The LMA (Figure 12 and 12A) is an inflatable silicone mask with a rubber connecting tube that is blindly inserted into the pharynx. Similar to the other devices described above, the tip of the inflated mask sits in the esophagus while fenestrations in the mask allow for ventilating the patient. The device is probably the easiest to use of all the devices. Some of the disadvantages are that it requires careful sizing to fit in the airway, does not prevent aspiration and that it is not a secure airway. While there are many variations of the LMA coming to market, including an intubating LMA, more information is needed.

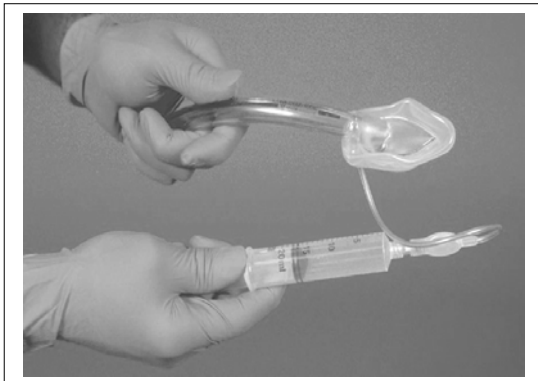


Figure 12

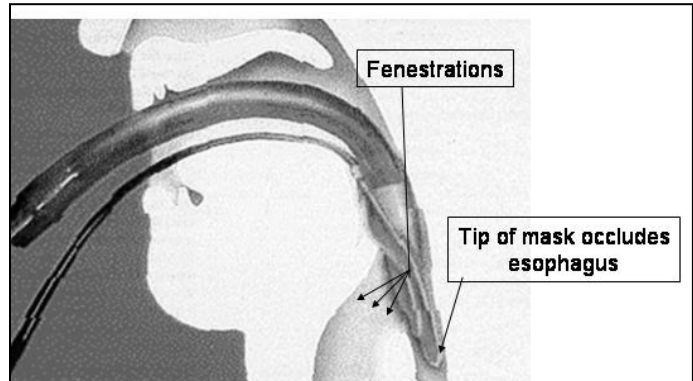


Figure 12A

VIDEO LARYNGOSCOPY

One of the most significant recent changes in airway management is video laryngoscopy (Figure 13). This technology involves placement of a micro-video camera on the laryngoscope blade that transmits glottic images to an external monitor allowing the operator to view the airway instead of looking directly through the mouth. There are several advantages including the ability to magnify the airway and to see the airway in much greater detail. This device is helpful in straightforward intubations along with the difficult airway, especially when patient movement is limited (i.e. spinal immobilization). This spring the department will be putting one of these devices, called the Glidescope, on the Rescue Medic units, as part of a pilot study. These devices are FDA-approved and specifically designed for field use. A slightly larger model is being

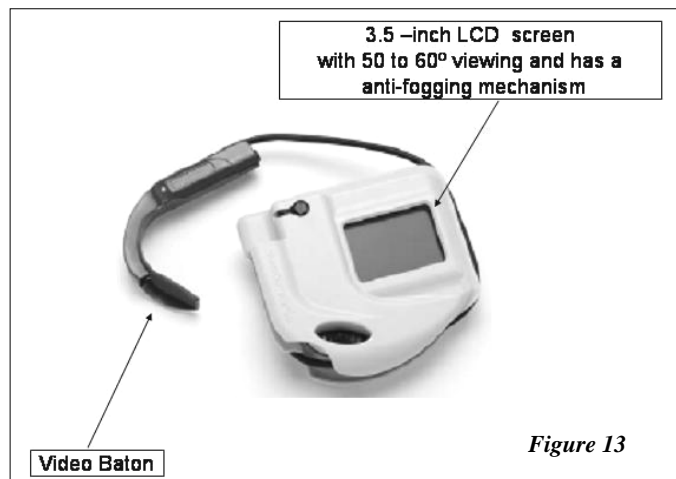


Figure 13

used in several hospitals by both anesthesia and emergency medicine physicians. The main drawback on these devices is the costs.

CONCLUSION

Airway management had changed little over time until recently. The most effective but yet underappreciated skill is BVM ventilation. Some of the pitfalls of BVM ventilation are inadequate position, failure to have a proper seal with the mask due to improper holding technique or incorrect sizing, and the failure to use oral and nasal airways. By taking some of the steps above you will more effectively be able to ventilate your patient. In addition, with some recent advances of airway devices, how we currently manage airways today may be different in a few years.

Submitted By:

Doug Isaacs, M.D.

Associate Medical Director

FDNY Bureau of Training

REFERENCES

- Rich, J.M. SLAM: Street Level Airway Management: Upper Saddle River, NJ: Pearson Prentice Hall; 2008.
- Walls, R.M., Murphy, M.F. Emergency Airway Management. 3rd Edition. Philadelphia, PA: Lippincott Williams & Wilkins; 2008.
- Pollak, A.N. Emergency Care in the Streets: 6th Edition. Sudbury, MA: Jones and Bartlett; 2008.

CME JOURNAL 2008-J012 QUIZ “BAG - VALVE MASK VENTILATION”

QUESTIONS

1. The jaw-thrust maneuver is the preferred method when opening a patient’s airway that has a suspected spinal injury.
 - A. True
 - B. False

2. An OPA is preferred over an NPA in a patient who has an intact gag reflex.
 - A. True
 - B. False

3. The two-handed mask hold technique creates a better seal than one-handed technique.
 - A. True
 - B. False

4. When ventilating a patient the goal should be which of the following:
 - A. Squeezing the bag until empty
 - B. Fast ventilations
 - C. Chest rise
 - D. One breath every 12 seconds

5. Cricoid pressure completely prevents regurgitation and aspiration of stomach contents into the lungs.
 - A. True
 - B. False

6. When securing an endotracheal tube in place it is recommended to tape along the mandible.
 - A. True
 - B. False

7. When transferring an intubated patient to a stretcher it is recommended to disconnect the BVM from the endotracheal tube.
 - A. True
 - B. False

8. The correct sizing an OPA is measured by which of the following methods (choose the **best** answer):
 - A. Center of the mouth to the angle of the jaw
 - B. Center of mouth to the tip of the ear lobe
 - C. Angle of the mouth to the tip of the ear lobe
 - D. Both A and C

9. Which of the following is **not** considered a supraglottic device?
- A. Combitube
 - B. OPA
 - C. King Airway
 - D. LMA
10. Ear-to-sternal notch position is better than “sniffing” position for aligning the oropharyngeal axes.
- A. True
 - B. False